ISSN : 0972-124X Jan - Feb 2013 Vol 17 | Issue 1

JISP

Official Publication of Indian Society of Periodontology

Journal of Indian Society of Periodontology

www.jisponline.com

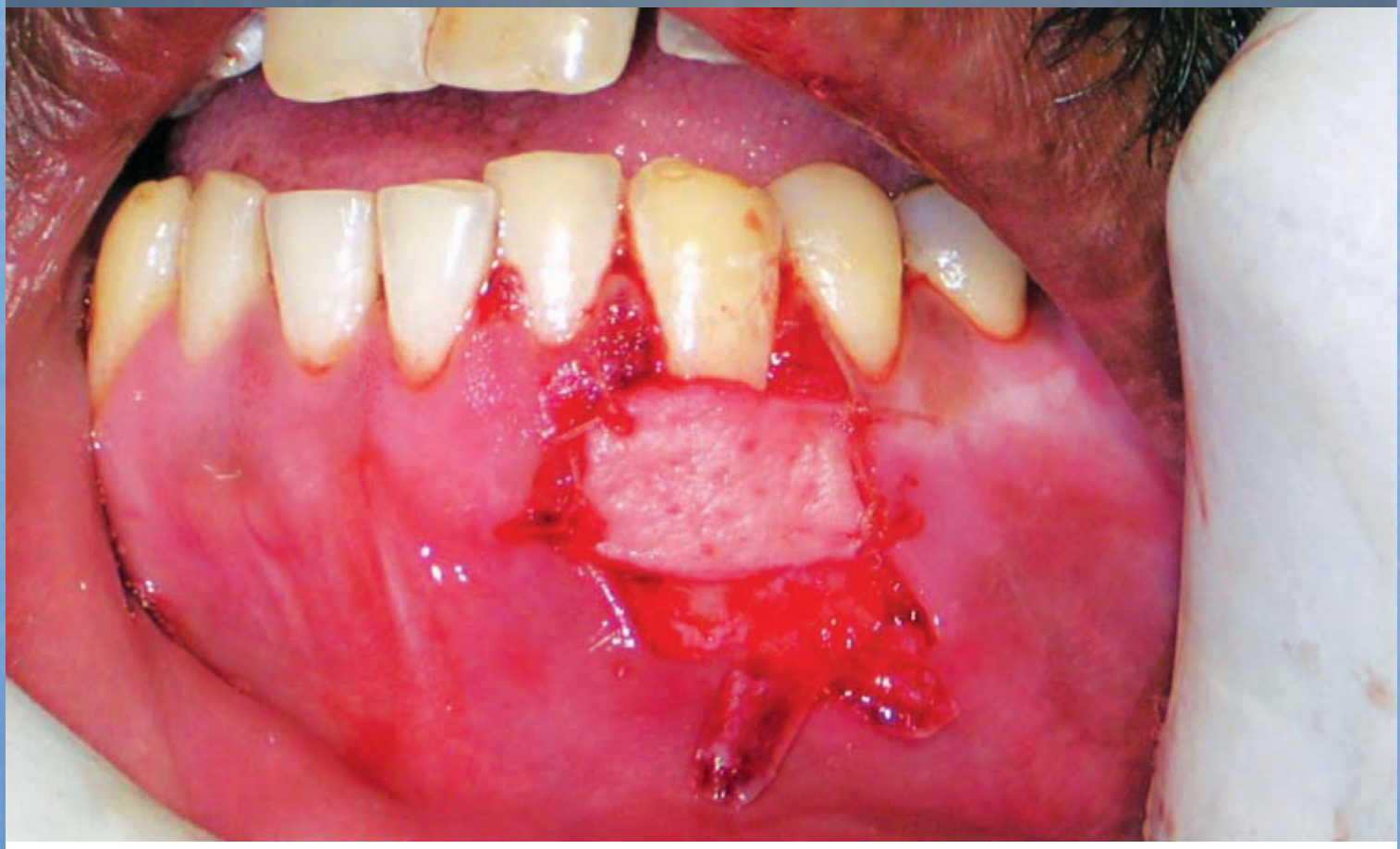

Wolters Kluwer Health | Medknow

PubMed Indexed

Case Report

Severe gingival enlargement associated with aggressive periodontitis

Shyam Padmanabhan, C. D. Dwarakanath[1]

Department of Periodontics, Vydehi Institute of Dental Sciences and Research Centre, [1]Vishnu Dental College, Bhimavaram, India

Abstract:

Enlargement of the gingiva can be due to various causes. Most prevalent are the inflammatory type and drug-induced type of gingival hyperplasia. However, sever enlargement associated with an aggressive type of periodontitis is an infrequent finding. Reported here is a case of a female patient aged 18 years who presented with severe enlargement of the maxillary and mandibular gingiva. Examination revealed enlargement extending up to the incisal edge of all the teeth and also an associated generalized loss of attachment with radiographic evidence of reduced bone height resembling an aggressive type of periodontitis. There were no associated systemic signs and symptoms or any family history except that there was generalized vitiligo of the skin and oral mucous membrane. The case was treated by gross electrosection of the gingiva.

Key words:

Aggressive periodontitis, electrosection, gingival enlargement, gingival hyperplasia, idiopathic gingival fibromatosis

Access this article online

Website: www.jisponline.com

DOI: 10.4103/0972-124X.107486

Quick Response Code:

Address for correspondence:
Dr. Shyam Padmanabhan, 403/1B T5, Anjaneya Annexe, GM Palya, New Thippasandra Post, Bangalore - 560 075, India.
E-mail: drshyamp@gmail.com

Submission: 02-11-2011
Accepted: 12-09-2012

INTRODUCTION

Gingival fibromatosis, gingivomatosis,[1] diffuse fibroma,[2] idiopathic fibromatosis, hereditary gingival fibromatosis, familial elephantiasis,[3] elephantiasis gingivae, congenital hypertrophy of gingiva, fibromatosis gingivae, gigantism of gingiva, symmetric fibroma of palate, congenital macrogingivae, hereditary gingival hyperplasia, and hypertrophic gingiva are slowly progressive fibrous enlargement of the maxillary and mandibular gingiva.

Gingival fibromatosis may be an inherited condition as in hereditary gingival fibromatosis, or may be associated with medications or may be idiopathic. They may also be caused by inflammation or leukemic infiltration.

It is characterized by massive gingival enlargement that appears to cover the tooth surfaces and displace the teeth. Whilst the cause of the disease is unknown, there appears to be a genetic predisposition.[4,5] Most idiopathic enlargements are probably caused by a genetic disorder and should, therefore, not be called idiopathic. However, it has not been proven on which gene this genetic disorder is located; thus, all enlargements without cause should still be described as idiopathic.

The syndromes associated with GF include

- Rutherford's syndrome (corneal dystrophy),
- Jones' syndrome (progressive deafness),
- Murray – Puretic Drescher syndrome (multiple hyaline fibromas),
- Laband syndrome (ear, nose, bone, and nail defects with hepatosplenomegaly),
- Cross syndrome (microphthalmia, mental retardation, athetosis, and hypopigmentation)[6]
- Cornelia de Lange Syndrome (primordial growth deficiency, severe mental retardation, anomalies of the extremities, and a characteristic face)[7]
- Ramon's syndrome (association with cherubism),
- hypothyroidism,
- chondrodystrophia and diffuse osteofibromatosis (GF with osteofibrosis)[7]
- Wynne and colleagues[8] have reported a syndrome which is associated with hearing deficiencies, hyperteloeism, and presence of supernumerary teeth.

Aggressive periodontitis is a genetically inherited disease that represents a severe and rapidly progressive form of periodontitis.[9] A rare case of a nonsyndromic, idiopathic gingival enlargement associated with generalized aggressive periodontitis has been reported twice before.[10,11]

We report a severe case of gingival enlargement associated with aggressive periodontitis and its management.

CASE REPORT

In the end of November 2005, an 18-year-old unmarried girl presented herself to the Department of Periodontology, The Oxford Dental College and Hospital, complaining of swollen gums in her upper and lower jaws. One month back, the patient had undergone an

extraction adjacent to a localized swelling in the lower posterior teeth owing to hypermobility and pain. Post-extraction, the swelling gradually spread to envelop the entire dentition. She gave no previous history of any swelling and family history did not reveal anything of significance. The patient had received no other treatment except that she complained of frequent evening rise in temperature.

On physical examination, the patient was moderately built, but poorly nourished and anemic. She also had lack of extraoral melanin pigmentation. Three years back, she gave a history of having a wheatish complexion following which she developed hypopigmented patches on her forehead and arms. These hypopigmented areas soon spread to envelop the entire body. There was bilateral submandibular lymph node enlargement, which was tender and mobile. Her cheeks appeared to be swollen and she was unable to close her mouth due to severe enlargement.

Intraorally, the gingiva seemed to be grossly enlarged - Grade IV gingival enlargement.[12] The enlargement was firm and fibrotic accompanied by an inflammatory component probably due to her inability to maintain adequate personal oral hygiene. It was a generalized type of enlargement extending from the buccal to the lingual/palatal mucosa communicating interdentally exposing only the incisal edges of most teeth. The diffuse type of enlargement involved the marginal, interdental, and attached gingiva and was severe enough to displace the teeth out of occlusion. All the areas showed a combined probing depth with generalized mobility [Figure 1a–d]. Radiographically, orthopantamogram and full-mouth intra-oral peri-apical radiographs revealed the presence of remaining bone in the range of 30-35% [Figure 2a and b].

Laboratory tests

Laboratory tests, including blood biochemistry, were carried out, but failed to show any abnormality [Tables 1 and 2].

Histologic examination

Incisional biopsy was performed which showed stratified squamous epithelium and acanthosis at a few places. The subepithelial tissue was edematous and consisted of thin and delicate collagen fibers. The connective tissue was highly vascular with a number of capillaries infiltrated with lymphocytes and plasma cells and a few neutrophils and eosinophils suggestive of chronic non-specific inflammatory gingival hyperplasia.

Treatment

Due to the severity of the enlargement, initial therapy and subsequent oral hygiene maintenance were not possible. Full mouth gingivectomy was performed by electro-section and electro-coagulation method under local anesthesia. The surgery was performed sextant wise in six sittings. Supra- and subgingival scaling were performed under antibiotic coverage (Ciplox – TZ bd for 10 days) following 1 week after the last surgical procedure. Initially gross debulking cuts were given with an intention of undertaking a second step pocket reduction therapy with possible regenerative periodontal surgery [Figure 3a and b].

Due to personal reasons the patient did not return for the second procedure. Six-month post-operative when the patient visited the department, it was found that there was no recurrence and the patient was able to maintain oral hygiene adequately. Intraoral examination revealed a marked reduction in probing pocket depth with reduction in mobility of most teeth except the upper right first molar (# 16) tooth which presented itself with a soft and edematous swelling and exudation [Figure 4a-d].

Radiographically, there was marked improvement in the crestal bone pattern except in 16 which showed extensive periapical pathology and was subsequently indicated for extraction.

An important observation made was that the patient developed patches of hyperpigmentation extraorally within a span of 6 months post-operatively.

DISCUSSION

Gingival fibromatosis (GF) is frequently part of various syndromes. It has been associated with mental retardation, Rutherford syndrome (GF and corneal dystrophy), Laband syndrome (IGF,

Table 1: Clinical biochemistry

Investigation	Normal value	Result
Alkaline phosphatase	67-190 U/L	120
SGPT/ALT	12-32 U/L	11 U/L
AST/SGOT	4-36 U/L	16 U/L
Total bilirubin	Upto 1.0 mg/dl	0.8 U/L
Direct bilirubin	Upto 0.3 mg/dl	0.1 mg/dl
Total protein	6-8.3 g/dl	8.3 g/dl
Albumin	3.5-5.3 g/dl	4.2 g/dl
Serum calcium	8.4-10.2 mg/dl	9.5 mg/dl
GGT	0-80 U/L	09 U/L
A/G ratio	1-1.25	1.0
Globulin	2.5-3.5 g/dl	4.1 g/dl

Table 2: Blood investigation

Investigation	Normal value	Result
Hemoglobin (%)	12-16 g	11 g
Bleeding time	2-5 min	2'15"
Clotting time	3-8 min	3'30"
Total WBC count (%)	4000-11000 cells	10900 cells/ccm
	Polymorphs–50-60	69
	Lymphocyte–28-40	26
	Eosinophil–1.0-2	5
	Monocyte–1.0-2	1
	Basophil–0-1	0
MCV	84-93 fl	86.2 fl
MCH	27–38 Pg	28.9 Pg
MCHC (%)	32–36	32.9
Erythrocytes	$3.8\text{-}4.8\times10^6/mm^3$	$4.44\times10^6/mm^3$
Thrombocyte	$120\text{–}280\times10^3/mm^3$	$220\times10^3/mm^3$
Lipid profile tests		
Total Cholesterol	<200 mg/dl	138 mg/dl
Triglycerides	<150 mg/dl	106 mg/dl
HDL Cholesterol	>65 mg/dl	67 mg/dl
LDL Cholesterol	100 mg/dl	89 mg/dl
VLDL Cholesterol	<40 mg/dl	22 mg/dl
Rheumatoud factor igm class (nephelometry)	Upto 15 IU/ml	<10.40 IU/ml
Fasting serum/plasma glucose		
Fasting glucose levels (Hexokinase–Serum/Plasma)	<110 mg/dl	88.1 mg/dl
Estrogen		118 pg/ml
Progesterone		800 ng/Dl
Thyroid stimulating hormone	0.4-4.2 mcIU/ml	2.80 mcIU/ml

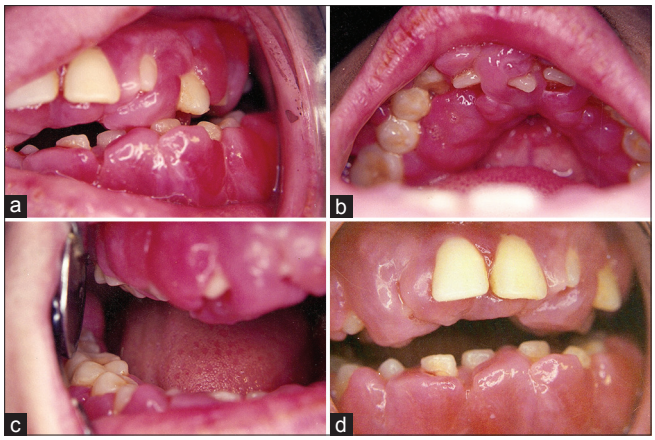

Figure 1: (a-d) Pre-operative photos showing severe gingival enlargement

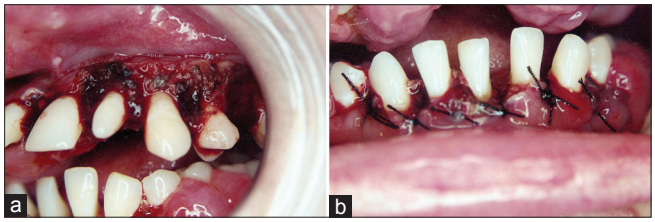

Figure 3: (a and b) Tissue after cauterization

ear, nose, nail, bone defects with heptosplenomegaly), Cross syndromes (GF microopthalmia, mental retardation, athetosis, and hypopigmented skin), Murray – Purelie-DrescherB (IGF with multiple hyaline fibromas), Jones syndromes (GF with sensorineural deafness), hypertrichosis, and epilepsy.

It can also be caused by a number of factors, including inflammation, leukemic infiltration, and medication use such as phenytoin, cyclosporine, or nifedipine.

Systemic diseases and conditions can affect the periodontium by two mechanisms.

- Manifestations of an existing inflammation initiated by dental plaque. This group of diseases, known as "conditioned enlargements," includes some hormonal conditions (e.g., pregnancy and puberty), nutritional diseases such as vitamin C deficiency, and some cases in which the systemic influence is not identified (nonspecific conditioned enlargement)
- Manifestation of the systemic disease independent of the inflammatory status of the gingiva.

The concept that the ovarian hormones may increase inflammation in gingival tissues and exaggerate the response to local irritants has been postulated in several studies. Gingival inflammation seems to be aggravated by an imbalance and/or increase in sex hormones.[13,14]

The patient did not elicit any history of hot flashes, mood swings, fatigue, headaches, insomnia, hair loss, weight gain, or any joint pains. She however confessed to being depressed due to her oral condition and frequent episodes of dry skin. Blood histochemistry did not reveal any abnormality suggestive of any hormonal imbalance. As the family, medical, prenatal, and

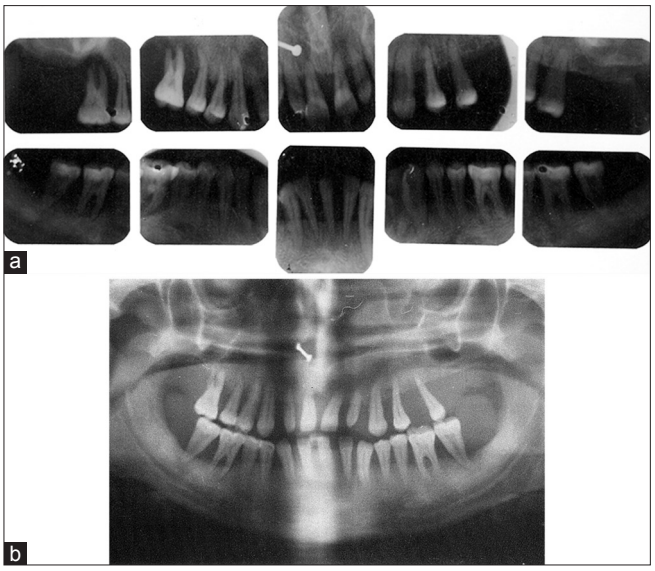

Figure 2: (a and b) Pre-operative radiographs

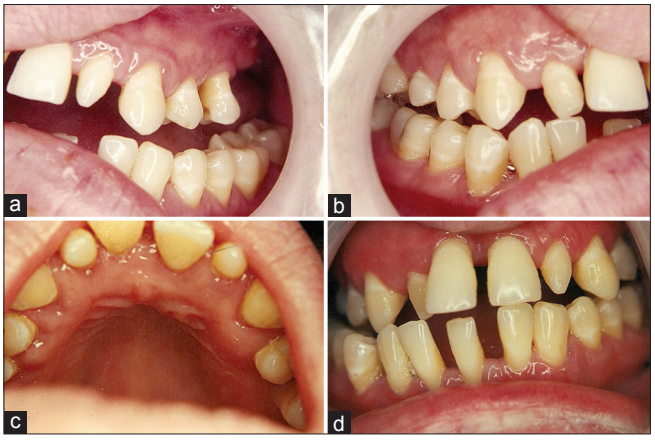

Figure 4: (a-d) 6-month post-operative photos

drug histories were noncontributory to this case, it was termed as idiopathic gingival fibromatosis (IGF).[14-17]

IGF manifests due to congenital or hereditary causes which is not clearly understood. Some authors have proposed the mode of transmission as autosomal dominant or recessive, suggesting abnormal chromosome on phenotype *2p21*.[9,18-20]

Recent findings have identified a mutation in the SOS-1 gene that segregates the hereditary gingival fibromatosis phenotype.[21] Identification of the specific genetic basis for hereditary gingival fibromatosis should help elucidate the pathogenic mechanisms that cause gingival enlargement.

The association between the periodontal findings and the loss of pigmentation (vitiligo) was a mere coincidence and did not fit into the criteria of any known syndromes known to mankind.

Vitiligo is usually associated with three autoimmune diseases:

- Addison's disease,
- Hyperthyroidism and
- Pernicious anemia.

Blood chemistry was not suggestive of any of the above-mentioned diseases.

Aggressive periodontitis is typically characterized by familial aggregation because of evidence of genetic predisposition that was derived from segregation analysis of affected families. Mendelian inheritance occurs and autosomal (dominant and recessive) transmission and X-linked transmission have been proposed. This patient had a diagnosis of generalized aggressive periodontitis with idiopathic gingival fibromatosis, based on her clinical findings and no history of familial aggregation.[22]

Syndromic form of periodontitis include, Papillon-Lefevre syndrome, Haim-Munk syndrome, Ehlers-Danlos syndrome, cyclic neutorpenia, cyclic familial neutropenia, Chediak-Hegashi syndrome, leukocyte adhesion deficiency Type I and Type II. Our patient did not fall into any of the above-mentioned syndromes.

To better understand the pathogenesis of the disease, knowledge of specific genetic factors that place individuals at greater risk for the development of gingival enlargement and severe forms of periodontitis would be essential for definitive diagnosis.

The results of the histopathologic evaluation of the biopsied tissues of our patient were consistent with those for fibrous gingival hyperplasia: the presence of a thickened acanthotic epithelium with elongated rete ridges and densely arranged collagen bundles with numerous fibroblasts, coupled with some sections that exhibited neovascularization.[23,24]

The presence of plasma cells was suggestive of a possible role of hypersensitivity reaction[25-28] and to clarify as plasma cell gingivitis, we examined the patient's dietary habits and various procedures, including use of toothpaste, mouthwashes, and abstaining from sweets and spices for a time. There was no apparent change observed in the gingiva. Our histologic findings were similar to a case of unusual gingival enlargement with rapidly progressive periodontitis previously reported by Hiroshi Nitta *et al*.[29]

The simplest, economical, and most available technology is cold steel surgery in the form of a scalpel blade or a gingivectomy knife (Orban or Kirkland). Since the gingiva has an excellent blood supply, cold-steel excision tends to be a very bloody procedure. Being time consuming and bloody, the cold-steel technique is least likely to cause collateral damage to surrounding tissues.

Another 'cold' technique involves the use of 12 fluted carbide burs in a high-speed dental hand-piece with a cooling spray of water directed at the bur tip as it cuts through the tissue.

Those who own a laser (CO_2 Nd: YAG, diode) seem to think it is a good choice for gingivoplasty. Reported advantages of laser surgery include sealing of the blood vessels during incision to maintain hemostasis and a clear field of view.

We preferred using electosurgery to treat the case due to the following advantages it possesses:

1. the units cost much less than do lasers;
2. the electrode cuts on its sides as well as on its tip;
3. the electrode may be bent to meet the clinical need;
4. cuts are made with ease when the device is set correctly;
5. hemostasis is immediate;
6. cutting is consistent;
7. the wound is nearly painless after the procedure;
8. the soft tissue has minimal trauma;
9. the tip is self-disinfecting.

The patient was monitored for recurrence of enlargement and breakdown of the periodontal apparatus for around 2 years. However, due to family constraints the patient was unable to come again.

CONCLUSIONS

We have highlighted a peculiar coexistence of nonsyndromic idiopathic gingival fibromatosis with generalized aggressive periodontitis. Diagnosis was based primarily on clinical, radiographic, and histopathologic assessments. However, further research including immulological and genetic testing is needed to establish a syndromic association between the two conditions.

REFERENCES

1. Ball EL. Case of Gingivomatosis or Elephantiasis of gingiva. J Periodontol 1941:12:26-8.
2. Buckner HJ. Diffuse Fibroma of the gums. J Am Dent Assoc 1937;27:2003-6.
3. Thukkral P. Idiopathic hyperplasia of the gingival – case report. J Indian Dent Assoc 1972:44:109-12.
4. Salinas CF. Orodental findings and genetic disorders. Birth Defcts Orig Artic Ser 1982;18:79-120.
5. Shapiro SD, Jorgenson RJ. Heterogeneity in genetic disorders that affect the orifices. Birth Defects Orig Artic Ser1983;19:155-66.
6. Ramer M, Marrone J, Stahl B, Burakoff R. Hereditary gingival fibromatosis: Identification, treatment, control. J Am Dent Assoc 1996;127:493-5.
7. Takagi M, Yamamoto H, Mega H, Hsieh KJ, Shioda S, Enomotos S. Heterogeneity in the gingival fibromatoses. Cancer 1991;68:2202-12.
8. Wynne SE, Aldred MJ, Bartold PM. Hereditary gingival fibromatosis with hearing loss and supernumerary teeth-a new syndrome. J Periodontol 1995;66:75-9.
9. Hart TC, Pallas D, Bowden DW, Bolyard J, Pettenati MJ, Cortelli JR. Evidence of genetic heterogenecity for hereditary gingival fibromatosis. J Dent Res 2000;79:1758-64.
10. Casavecchia P, Uzel MI, Kantarci A, Hasturk H, Dibart S, Hart TC. Hereditary gingival fibromatosis associated with generalized aggressive periodontitis: A case report. J Periodontol 2004;75:770-8.
11. Chaturvedi R. Idiopathic Gingival Fibromatosis Associated with Generalized Aggressive Periodontitis: A Case Report. J Can Dent Assoc 2009;75:291-5.
12. Angelopoulos AP, Goaz PW. Incidence of diphenylhydantoin gingival hyperplasia. Oral Surg Oral Med Oral Pathol 1972;34:898-906.
13. Pack AR, Thomson ME. Effects of topical and systemic folic acid supplementation on gingivitis in pregnancy. J Clin Periodontol 1980;7:402-14.
14. Thomson ME, Pack AR. Effects of extended systemic and topical folate supplementation on gingivitis of pregnancy. J Clin Periodontol 1982;9:275-80.
15. Gorlin RJ, Cohen MM, Levin LS. Syndromes of the head and neck.

3rd ed. New York: Oxford University Press; 1990.
16. Raeste AM, Collan Y, Kilpinen E. Hereditary fibrous hyperplasia of the gingival with varying penetrance and expressivity. Scand J Dent Res 1978;86:357-65.
17. Singer SL, Goldblatt J, Hallam A, Winters JC. Hereditary gingival fibromatosis with a recessive mode of inheritance: Case reports. Aust Dent J 1993;38:427-32.
18. Emerson TG. Hereditary gingival hyperplasia. A family pedigree of four generations. Oral Surg 1965;19:1.
19. Hart TC, Pallas D, Bowden DW, Bolyard J, Peltenati MJ, Cortelti JR. Cicnetic Linkage of Hereditary Gingival Fibromatosis to chromosome 2p21. Am J Hum Genet 1998;62:876-83.
20. Jorgenson RJ, Cocker ME. Variations in the inheritance and expression of the gingival fibromatosis. J Periodontol 1974;45:472-7.
21. Hart TC, Zhang Y, Gorry MC, Hart PS, Cooper M, Marazita ML. A mutation in the SOS1 gene causes hereditary gingival fibromatosis type 1. Am J Hum Genet 2002;70:943-54.
22. Meng H, Xu L, Li Q, Han J, Zhao Y. Determinants of host susceptibility in aggressive periodontitis. Periodontol 2000 2007;43:133-59.
23. Coletta RD, Graner E. Hereditary gingival fibromatosis: A systematic review. J Periodontol 2006;77:753-64.
24. DeAngelo S, Murphy J, Claman L, Kalmar J, Leblebicioglu B. Hereditary gingival fibromatosis-a review. Compend Contin Educ Dent 2007;28:138-43, quiz 144, 152.
25. Kerr DA, McClatchey KD, Regezi JA. Idiopathic gingivostomatitis. Cheilitis, glossitis, gingivitis syndrome; atypical gingivostomatitis, plasma-cell gingivitis, plasmacytosis of gingiva. J Oral Surg 1971;32:402-23.
26. Lubow RM, Cooley RL, Hartman KS, McDaniel RK. Plasma-cell gingivitis. Report of a case. J Periodontol 1984;55:235-41.
27. Serio FG, Siegel MA, Slade BE. Plasma cell gingivitis of unusual origin. A case report. J Periodontol 1991;62:390-3.
28. Sollecito TP, Greenberg MS. Plasma cell gingivitis. Report of two cases. Oral Surg Oral Med Oral Pathol 1992;73:690-693.
29. Nitta H, Kameyama Y, Ishikawa I. Unusual gingival enlargement with rapidly progressive periodontitis. Report of a case. J Periodontol 1993;64:1008-12.

How to cite this article: Padmanabhan S, Dwarakanath CD. Severe gingival enlargement associated with aggressive periodontitis. J Indian Soc Periodontol 2013;17:115-9.

Source of Support: Nil, **Conflict of Interest:** None declared.